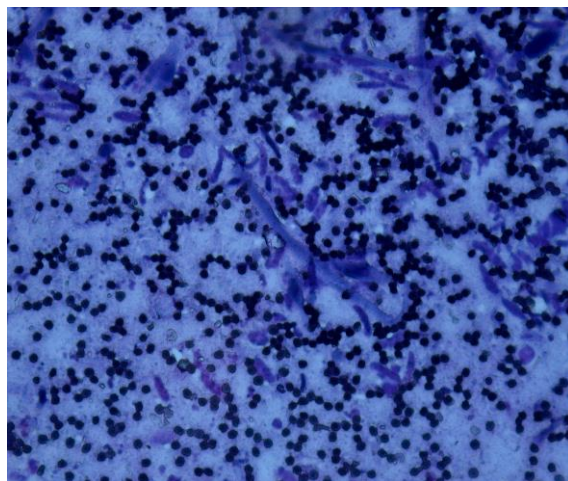


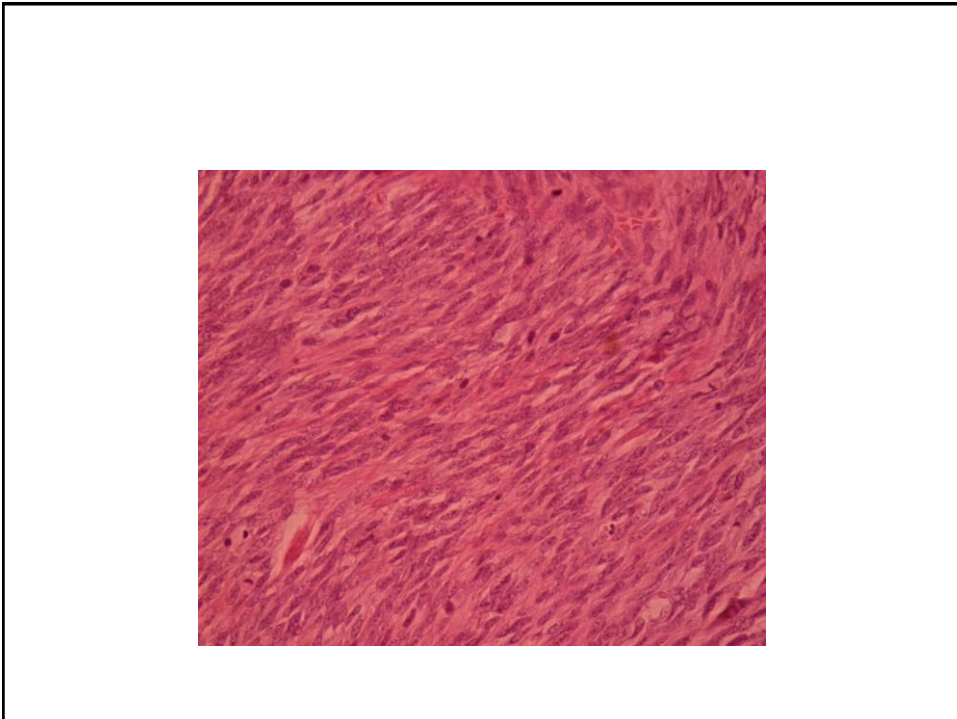
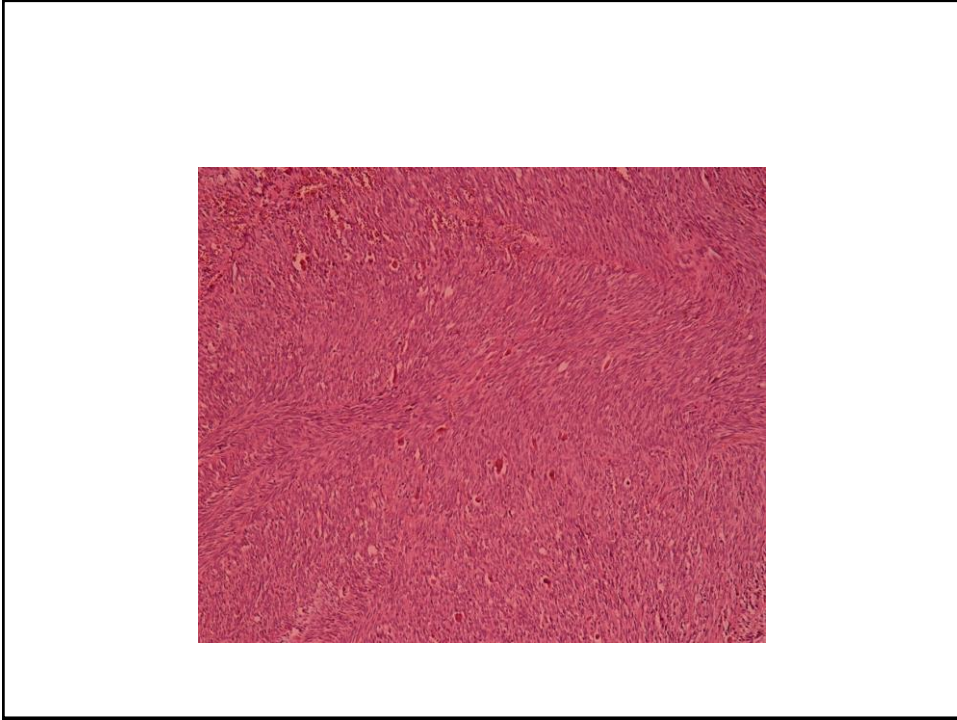
Опухоль крылонебной ямки

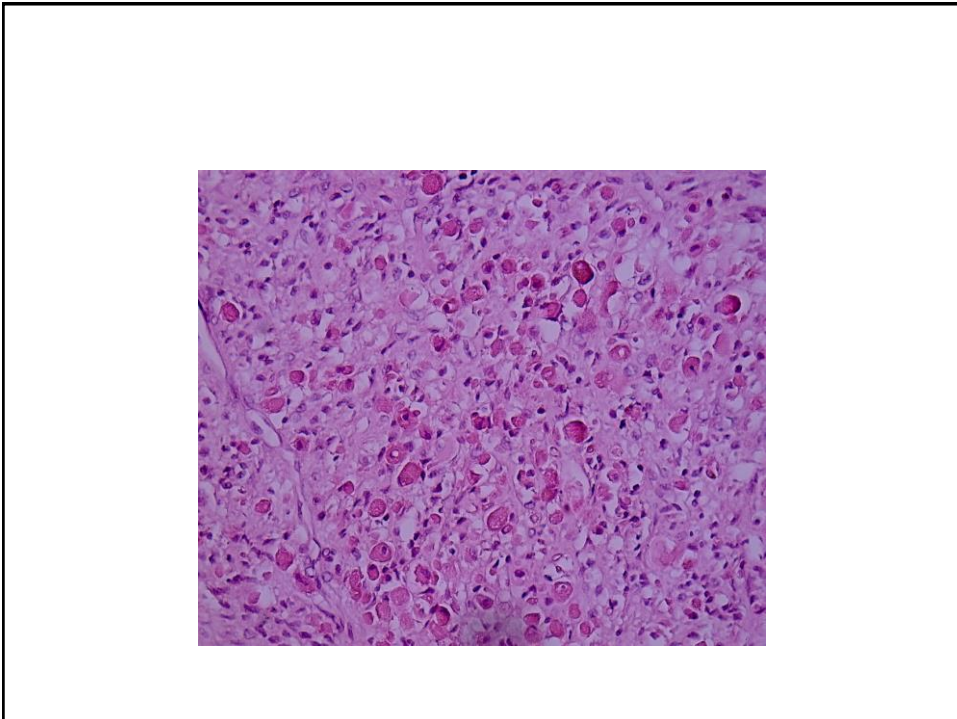
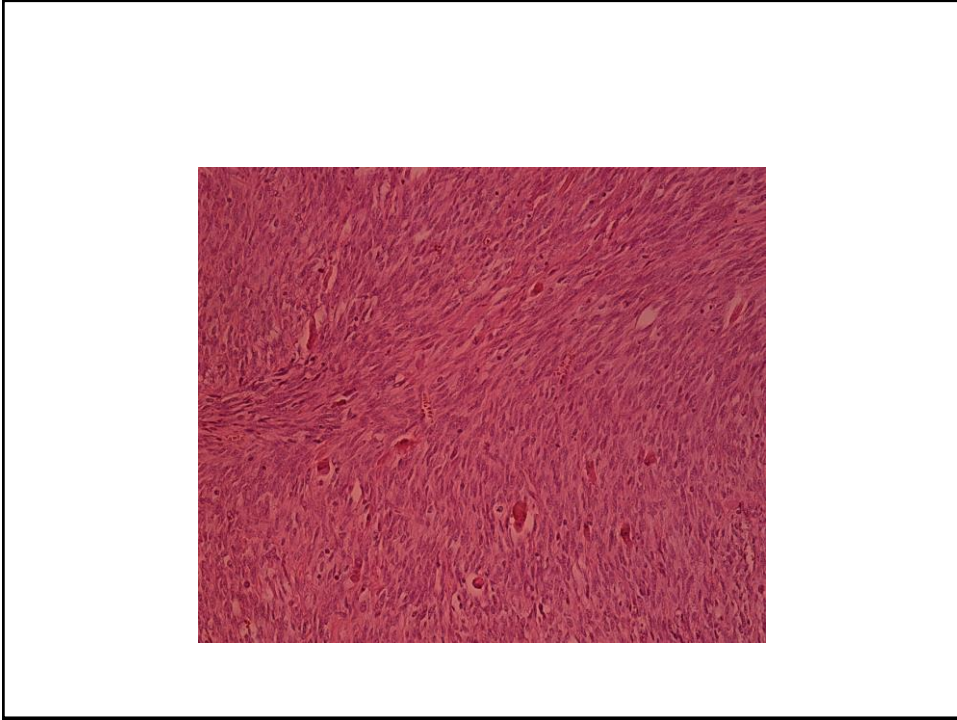
Женщина 38 лет

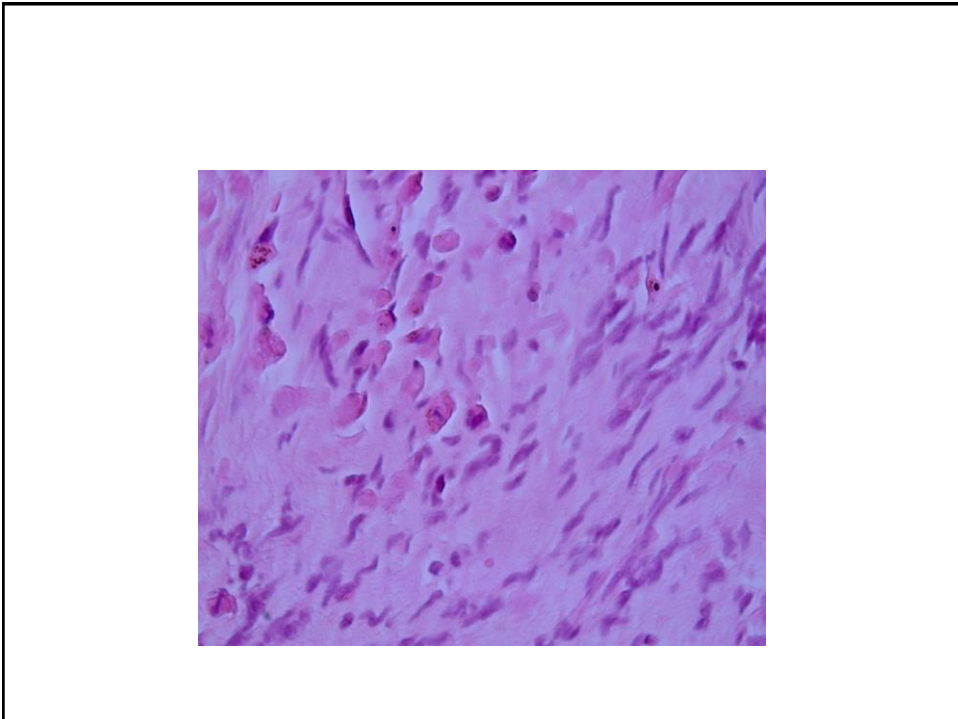
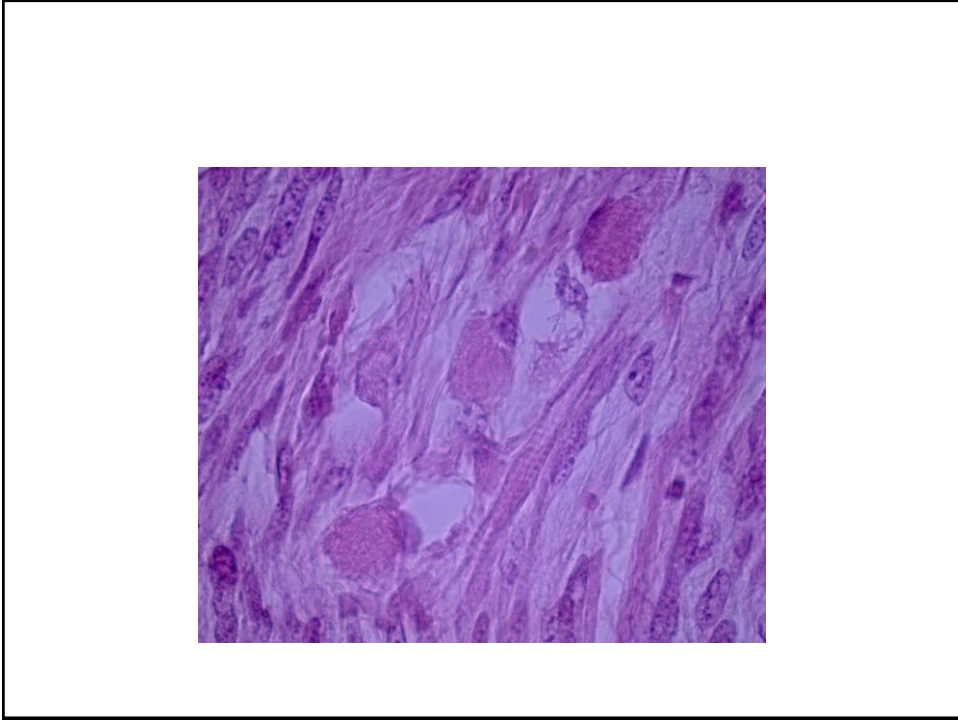
Нарастающие боли, КТ-картина
опухоли крылонебной ямки

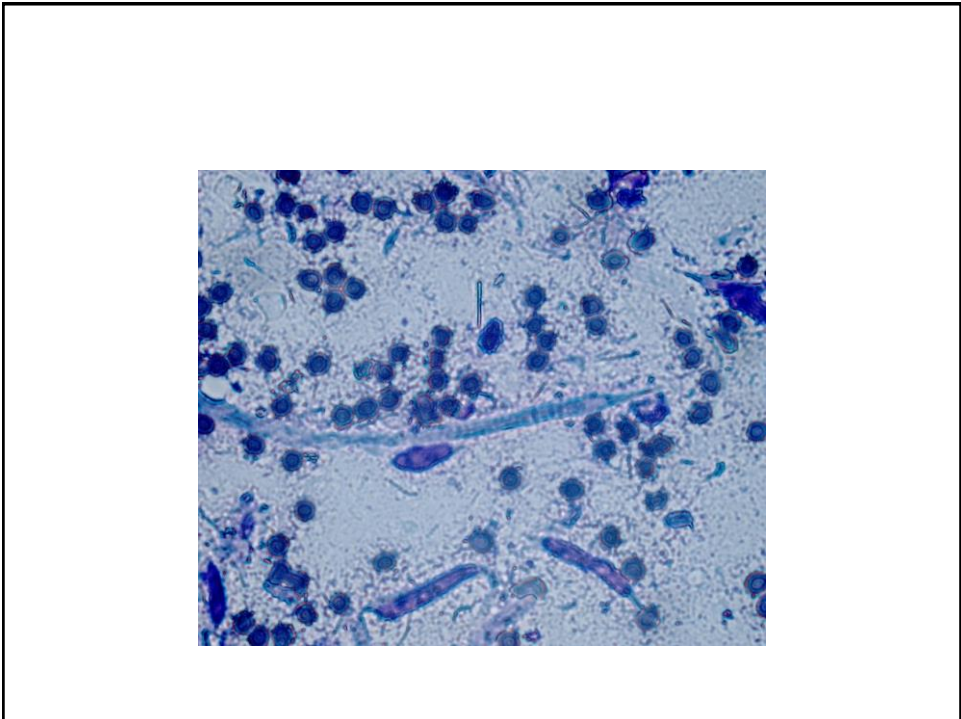
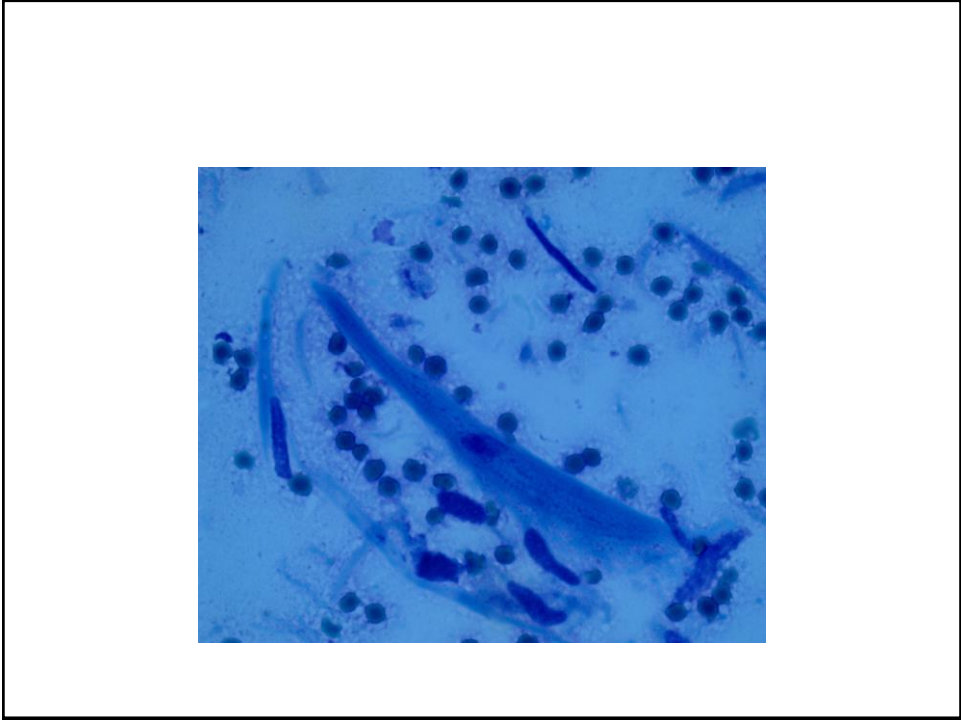
АПТИ

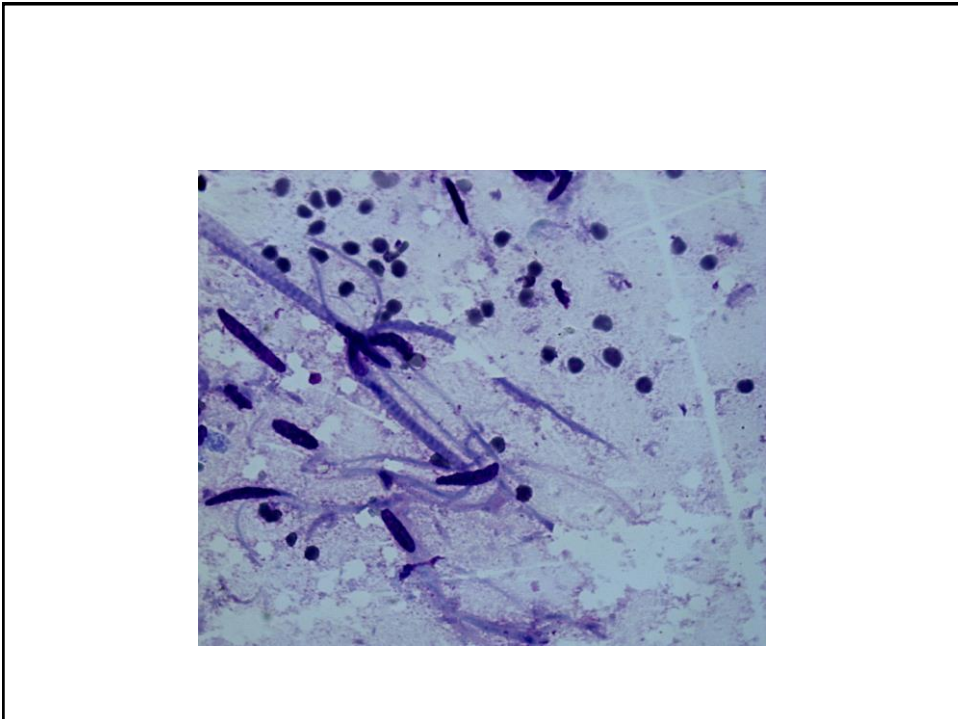
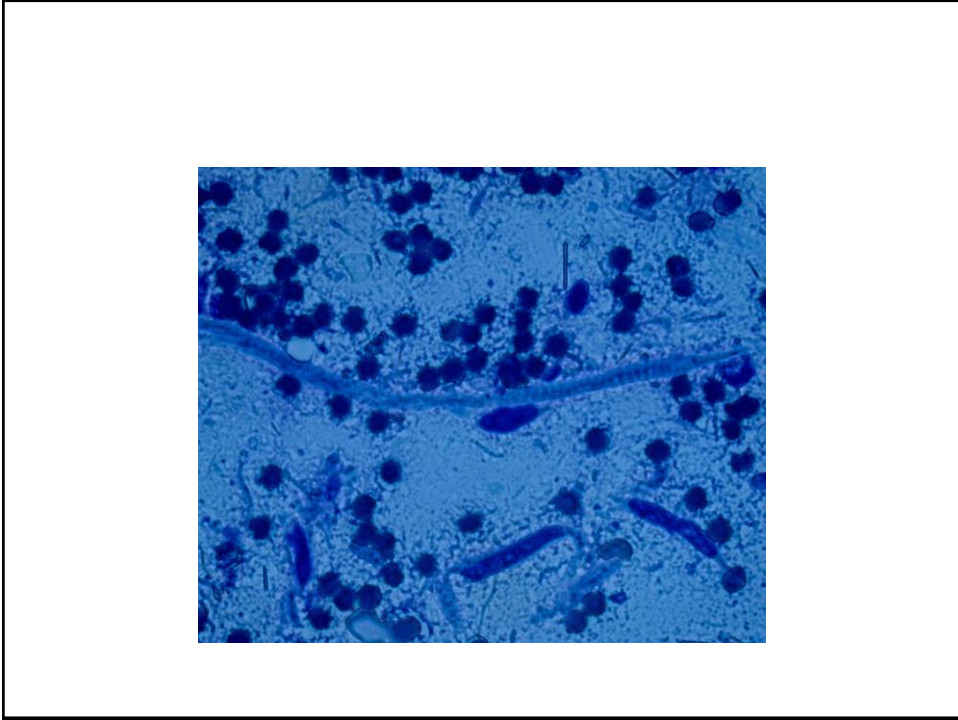


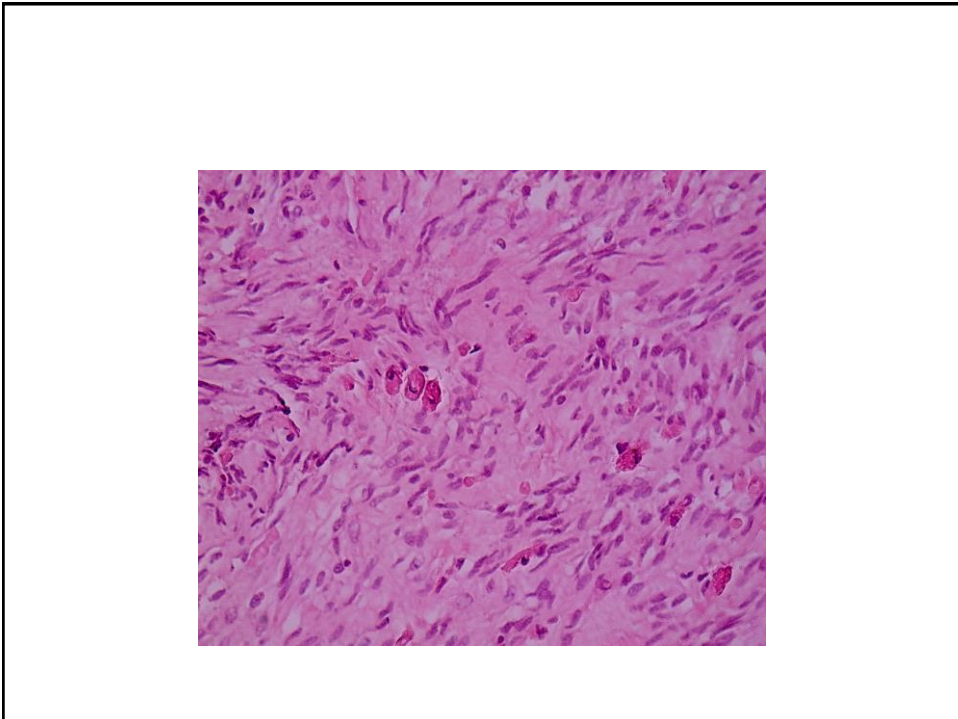
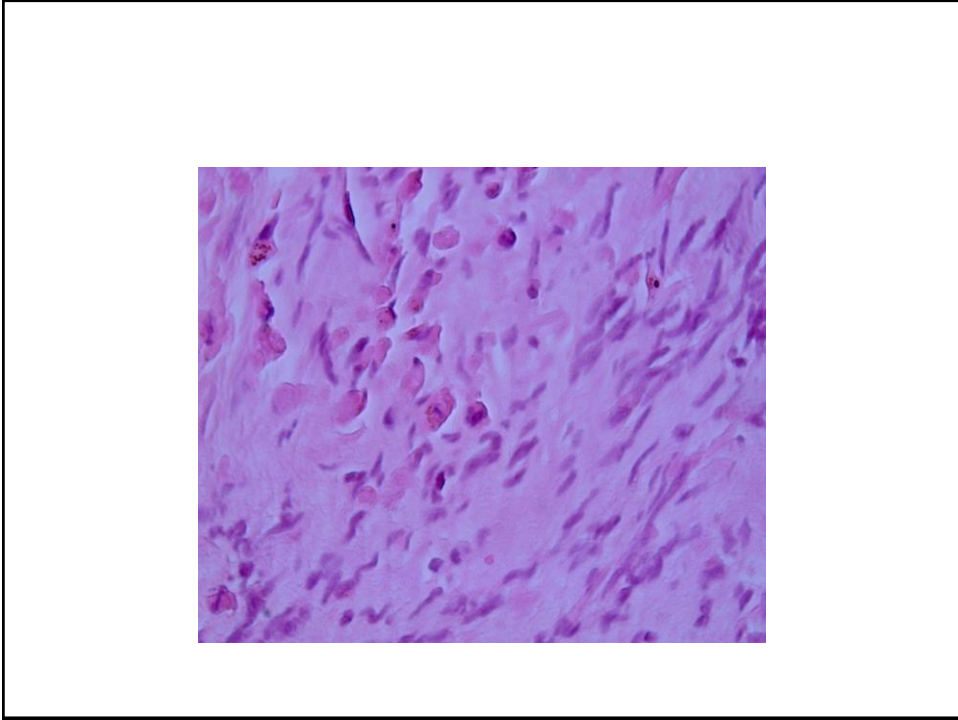


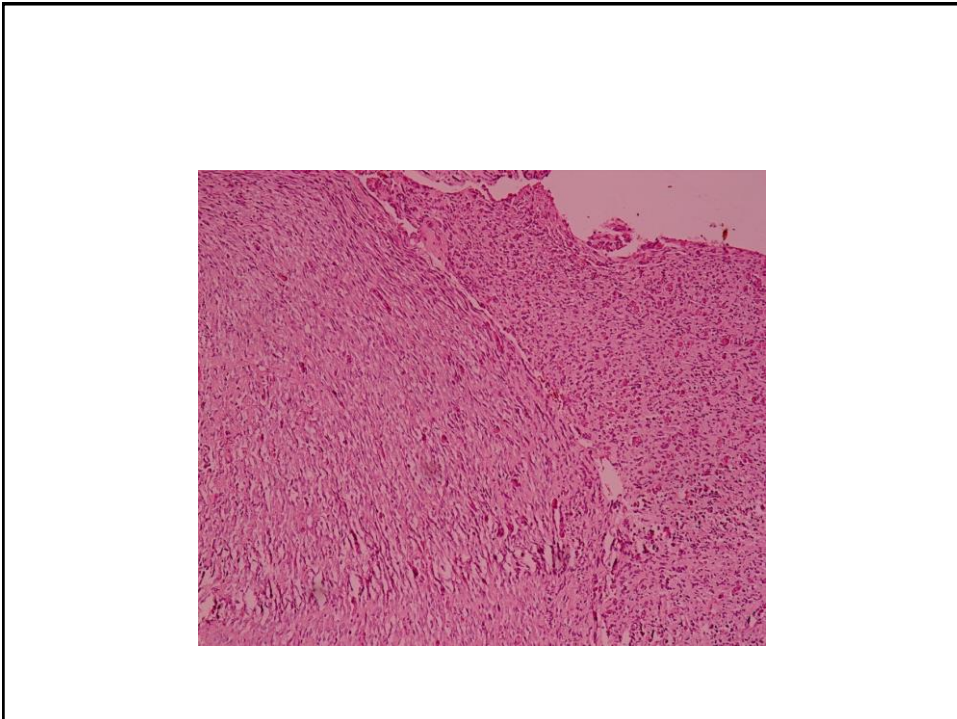
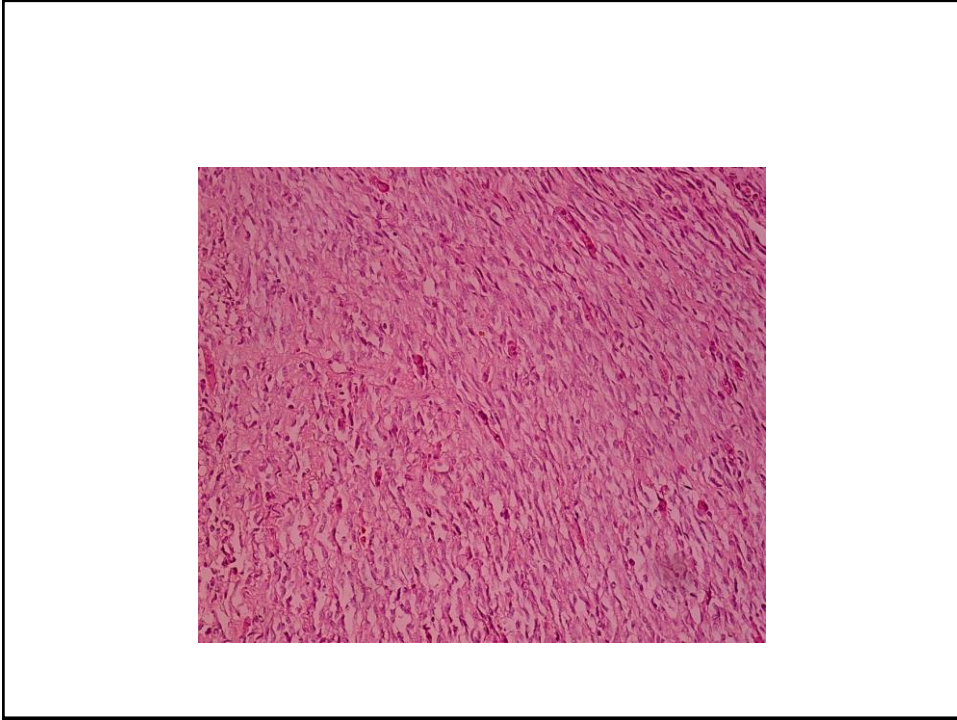


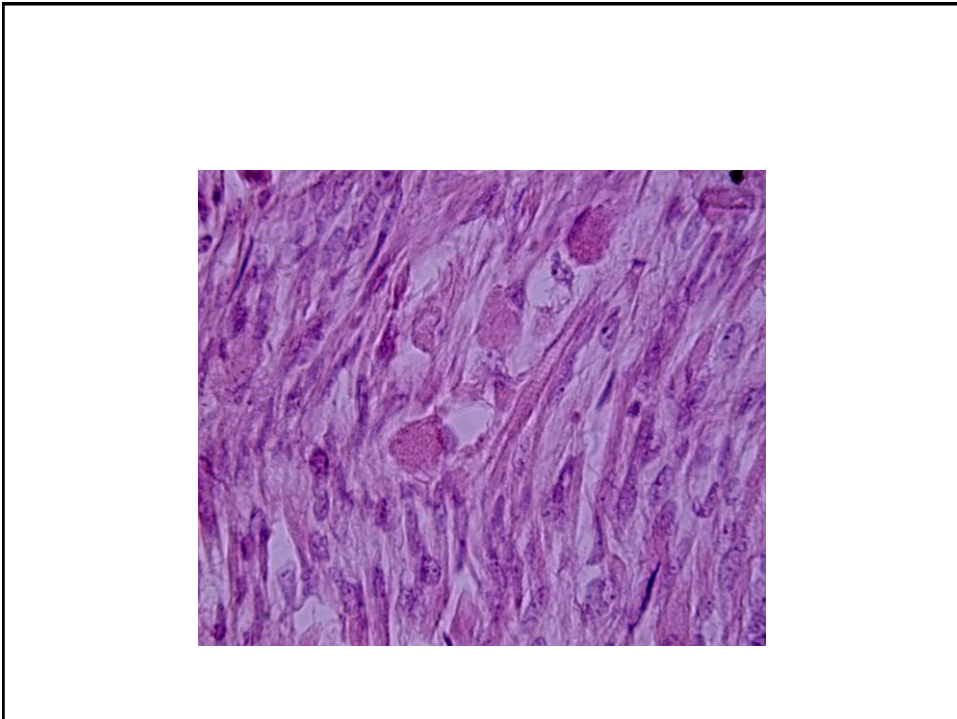
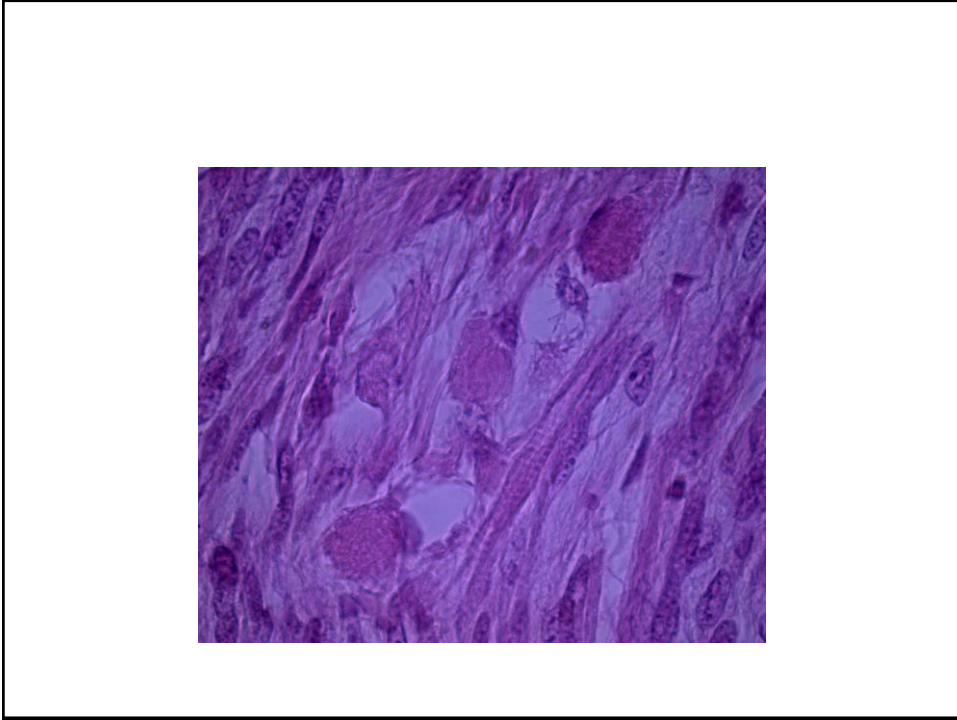












Тритон-опухоль