

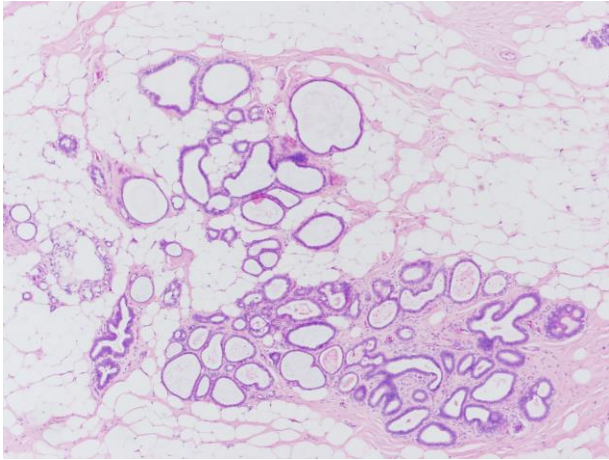
Case 2

- 58 year female nodular mass in the left breast.

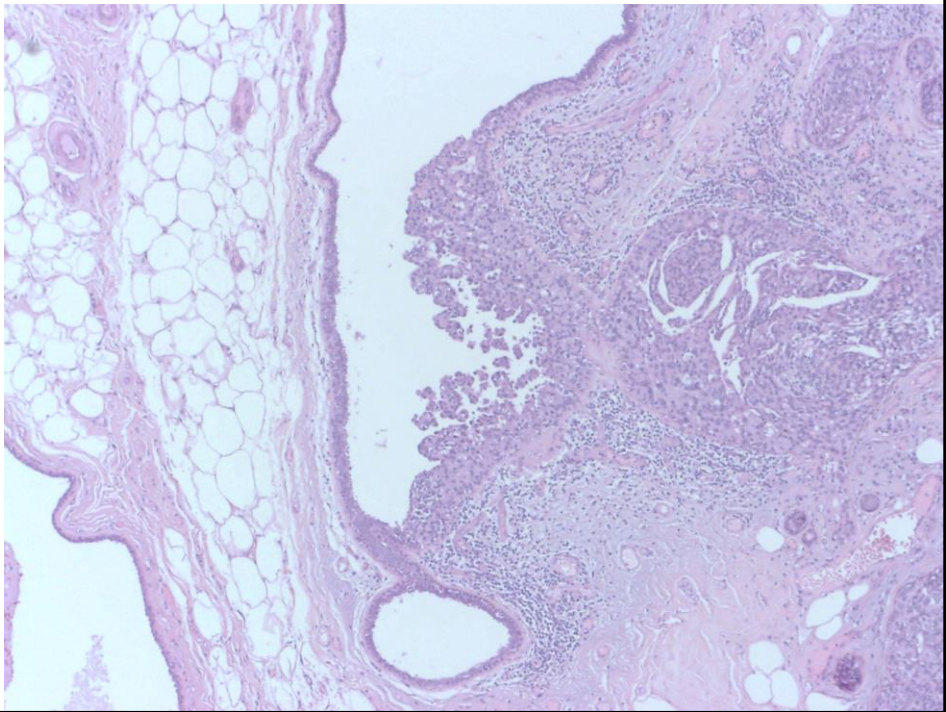
Cystic appearing breast tissue

- Microcalcifications
 - Fibrocystic changes/disease
 - Fat necrosis
 - Carcinoma (including Metastatic lesions)
 - Carcinoma (Post therapy)
- Mass forming
 - Fibrocystic changes/disease
 - Papillary lesions
 - DCIS
 - Carcinoma (including Metastatic and Post therapy lesions)

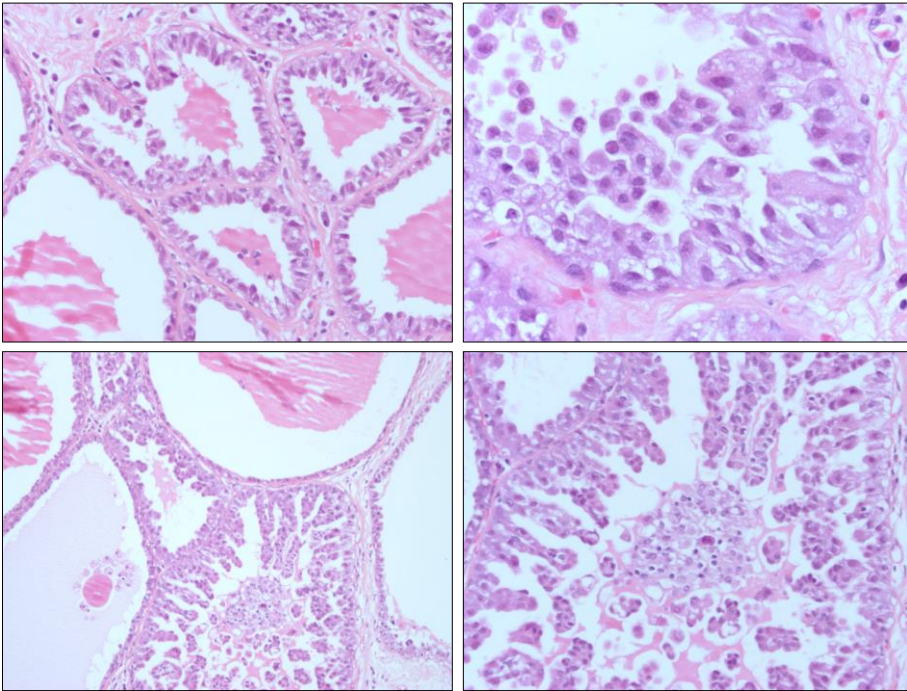
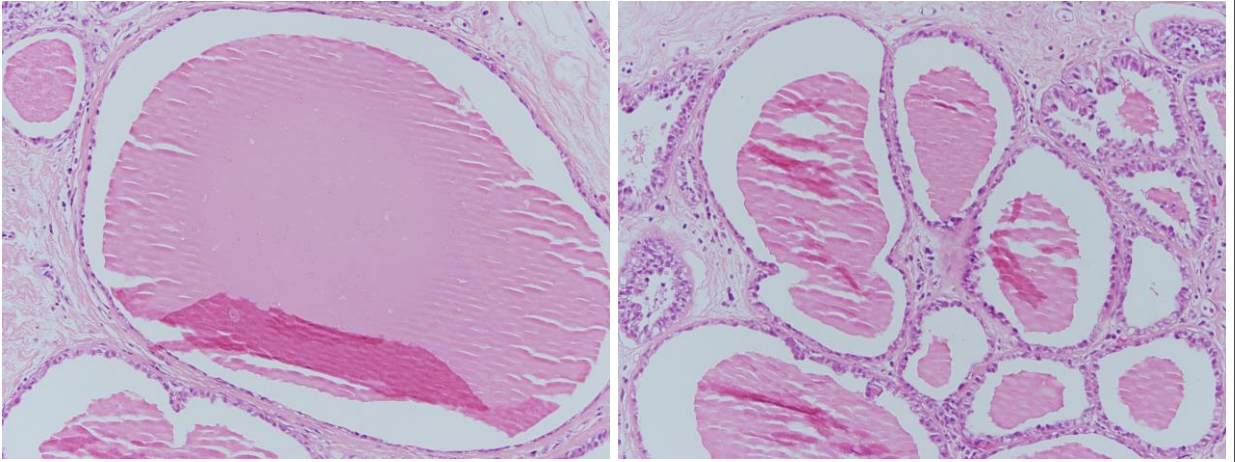
Dilated TDLU

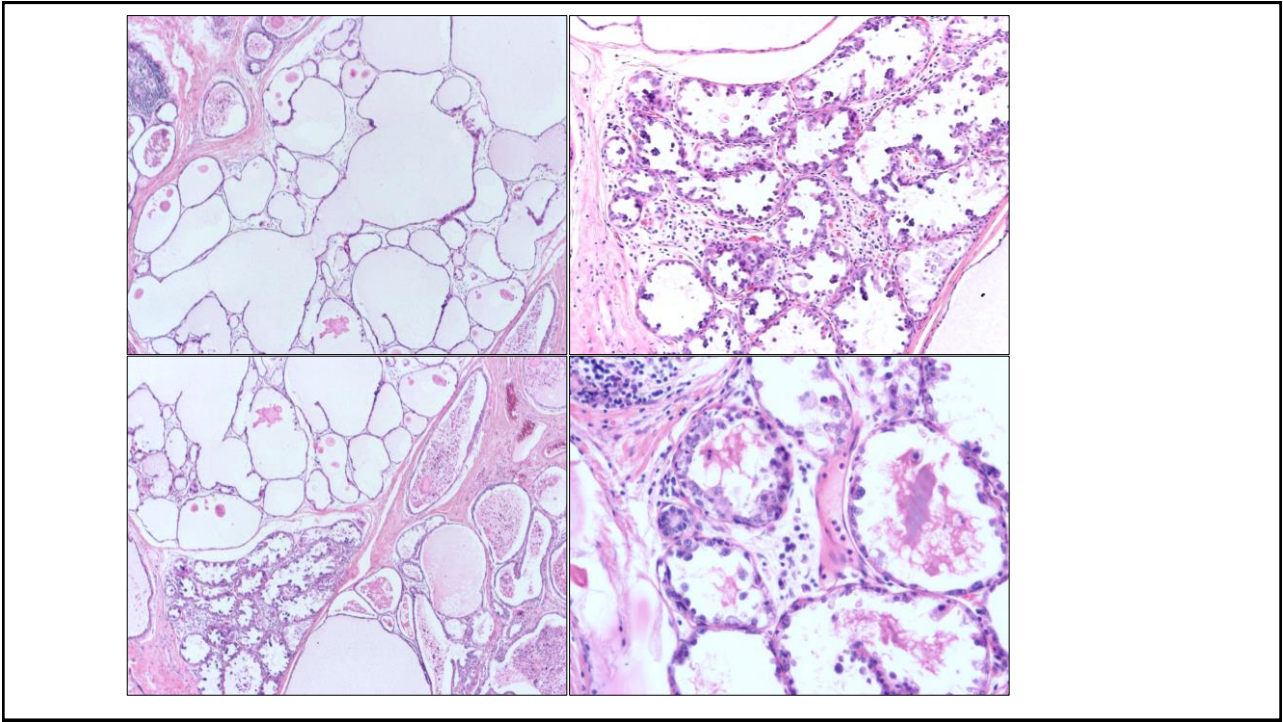


DCIS involving duct

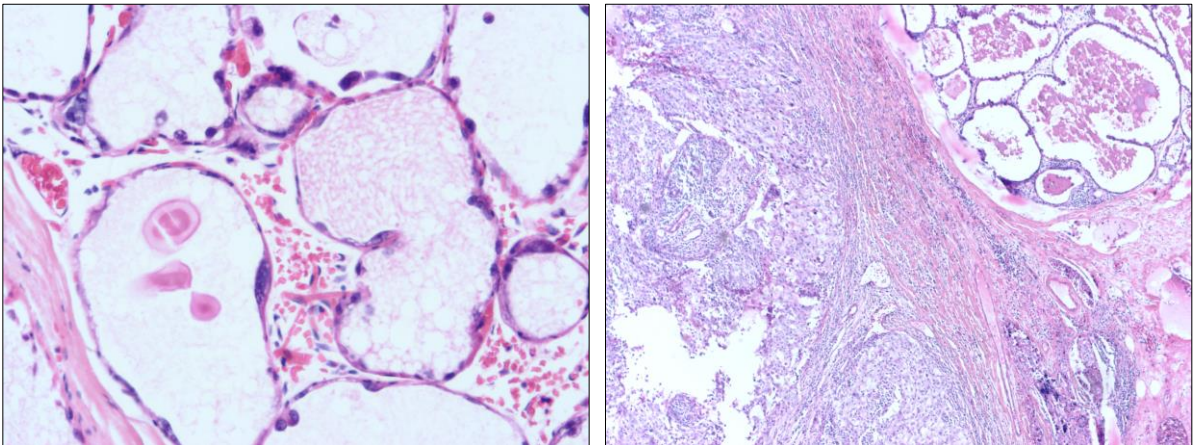


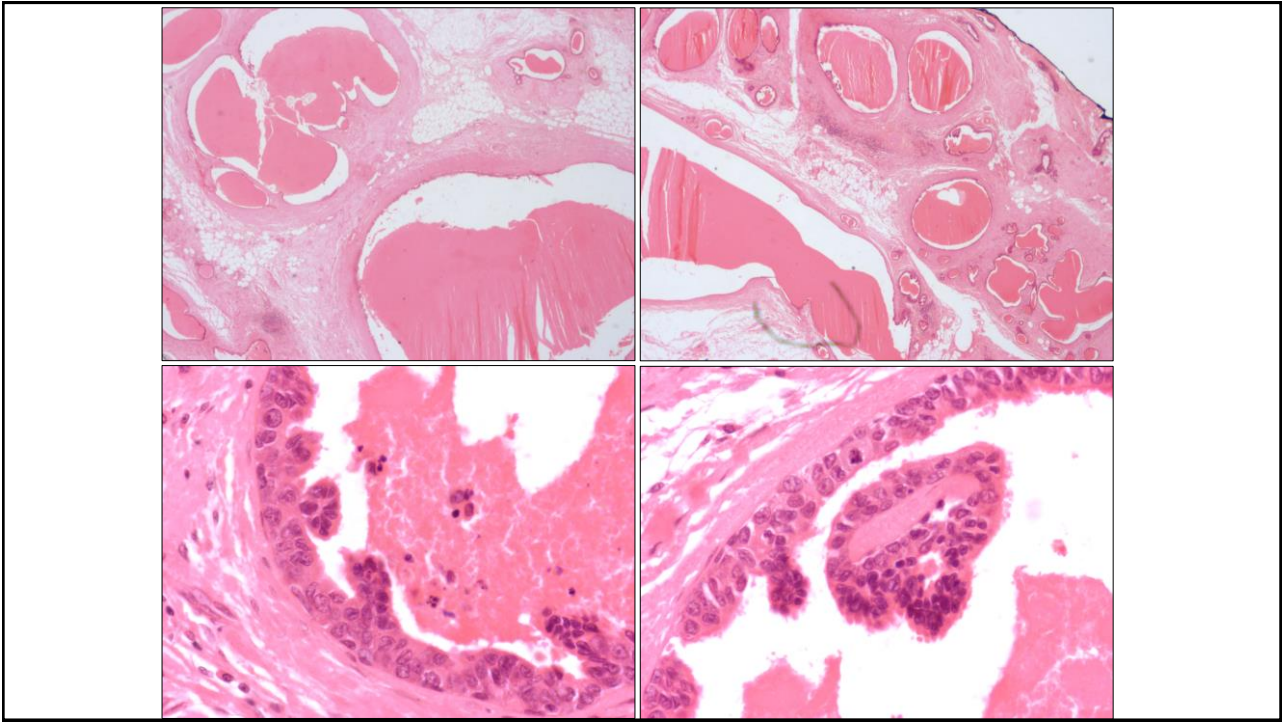
Cystic duct with secretions



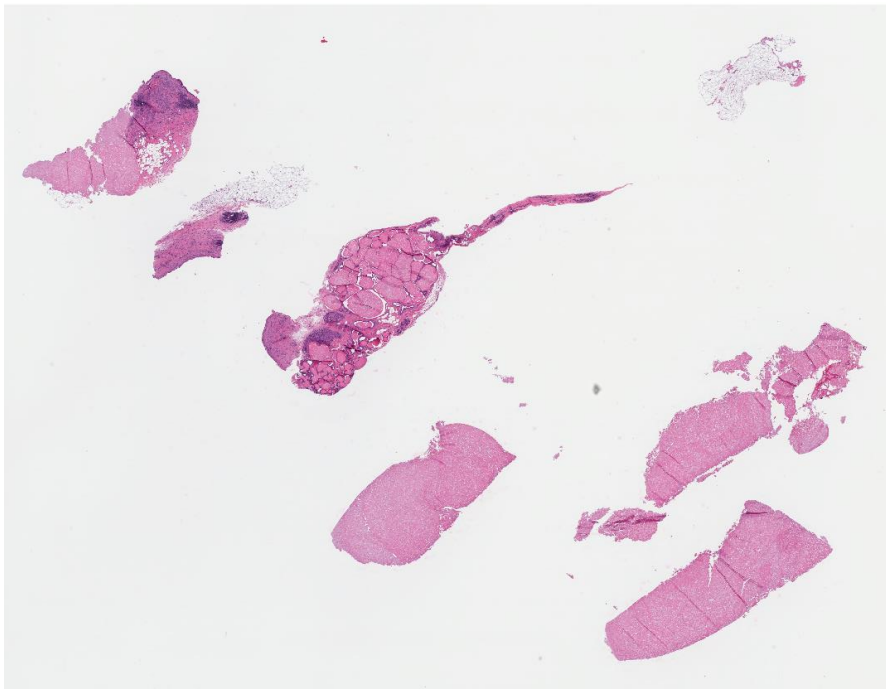


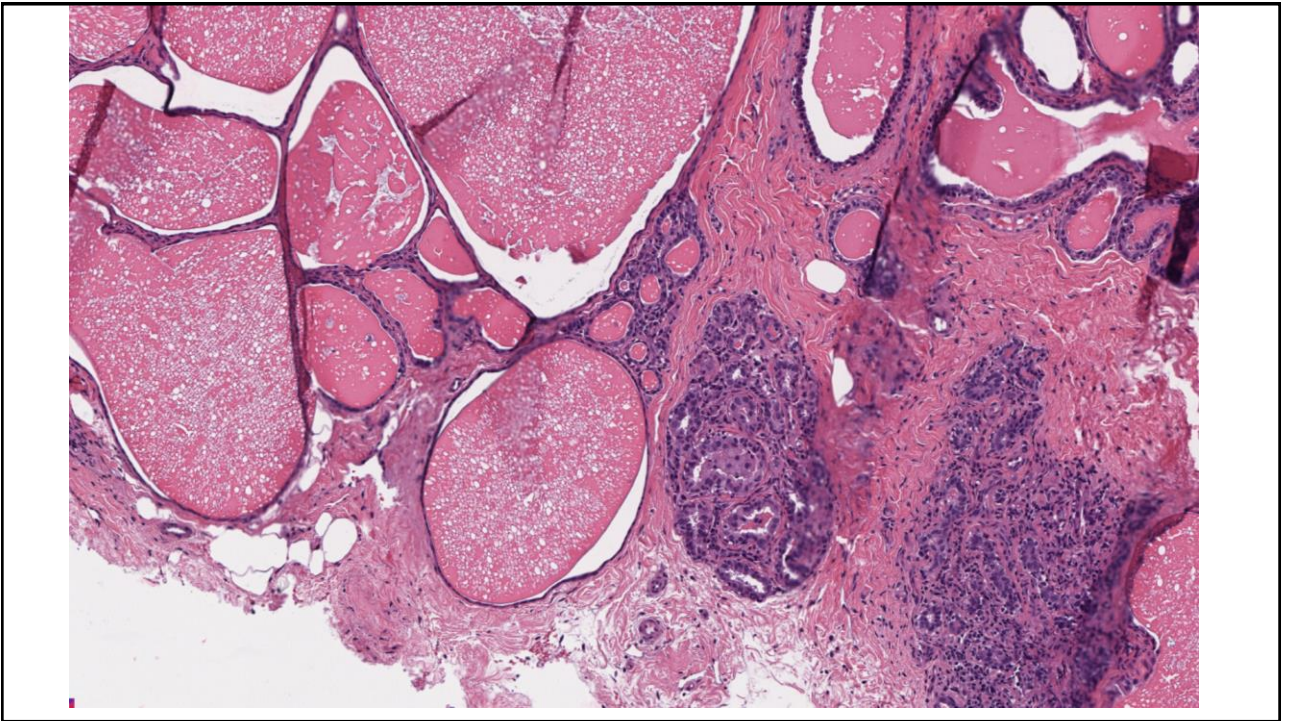
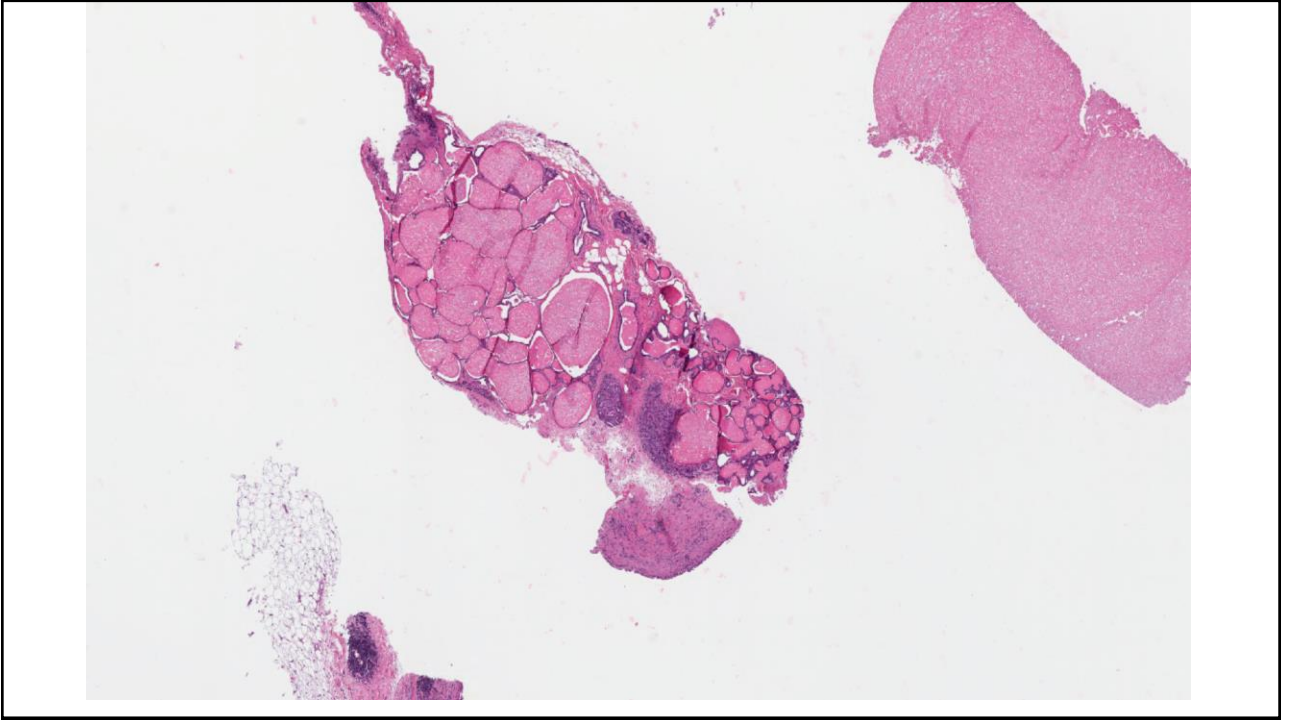
High grade cytology





Case 2

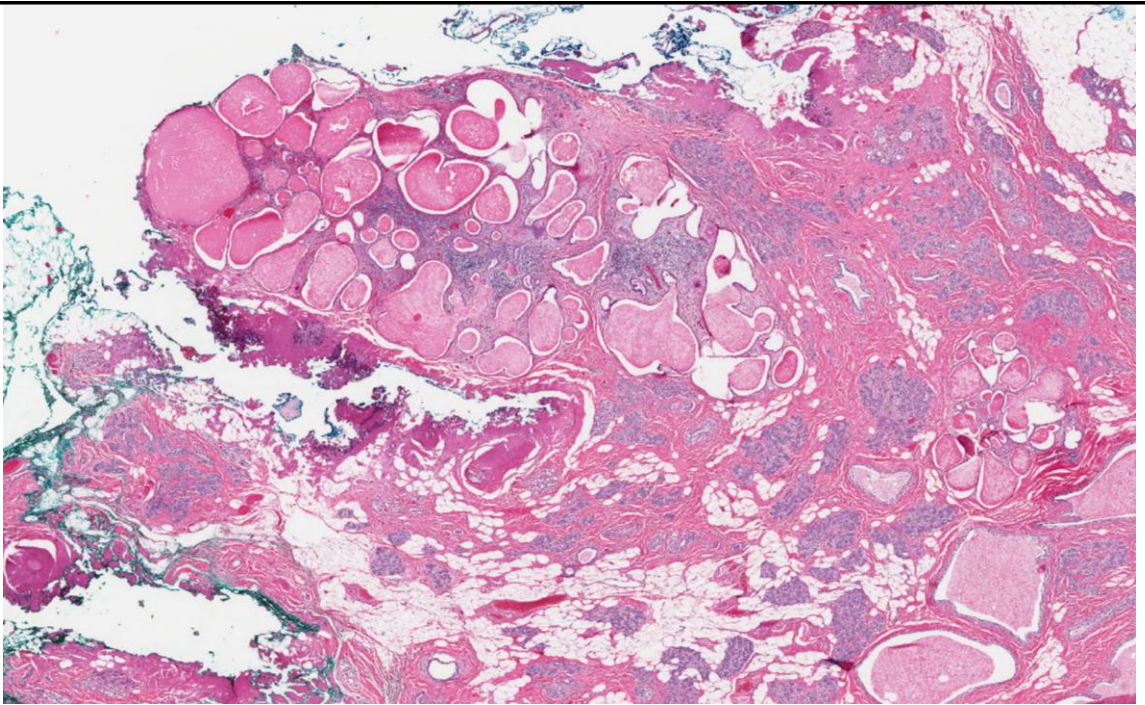


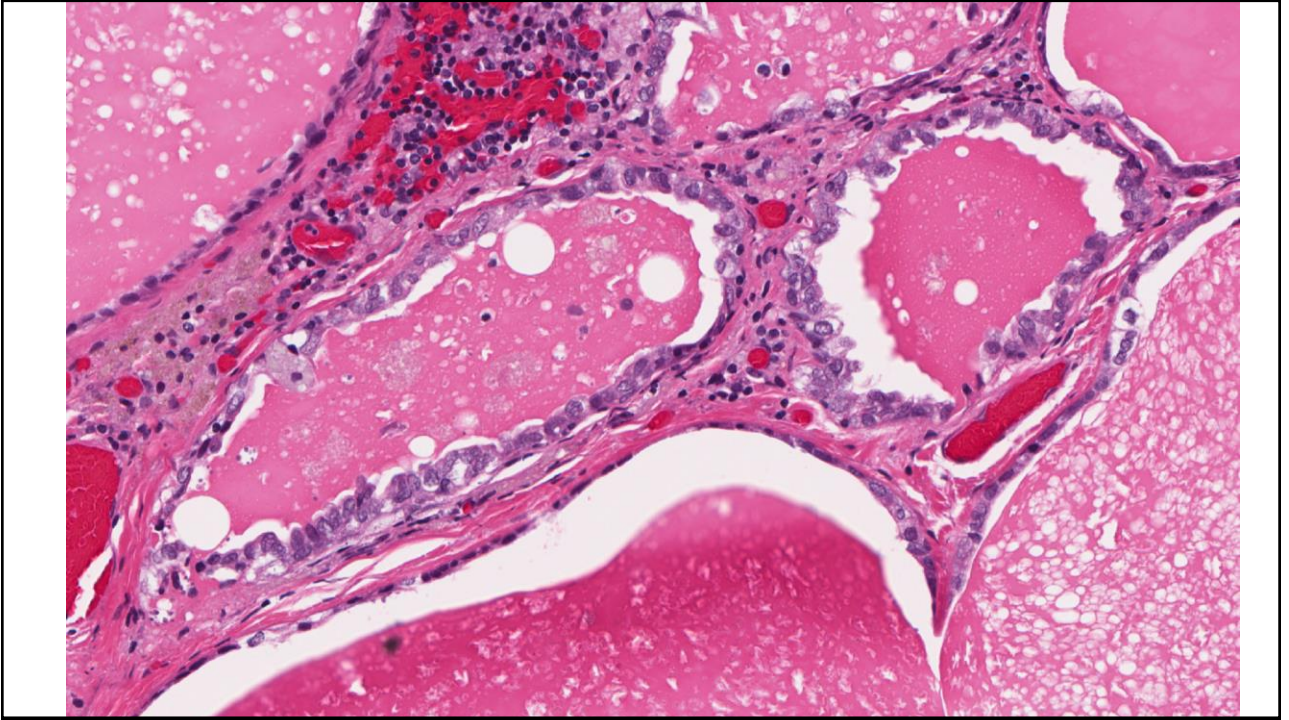


Current Case

- No cytologic atypia
- Conservative excision recommended
 - to rule out secretory carcinoma.

Excision





Final Diagnosis

- Cystic hypersecretory hyperplasia
- ? With atypia
- No evidence of carcinoma.

Take home messages

- Unusual conditions need to be recognized
- Atypia or malignancy not always needed for recommending excision
- Guiding the surgeon's hand!!!