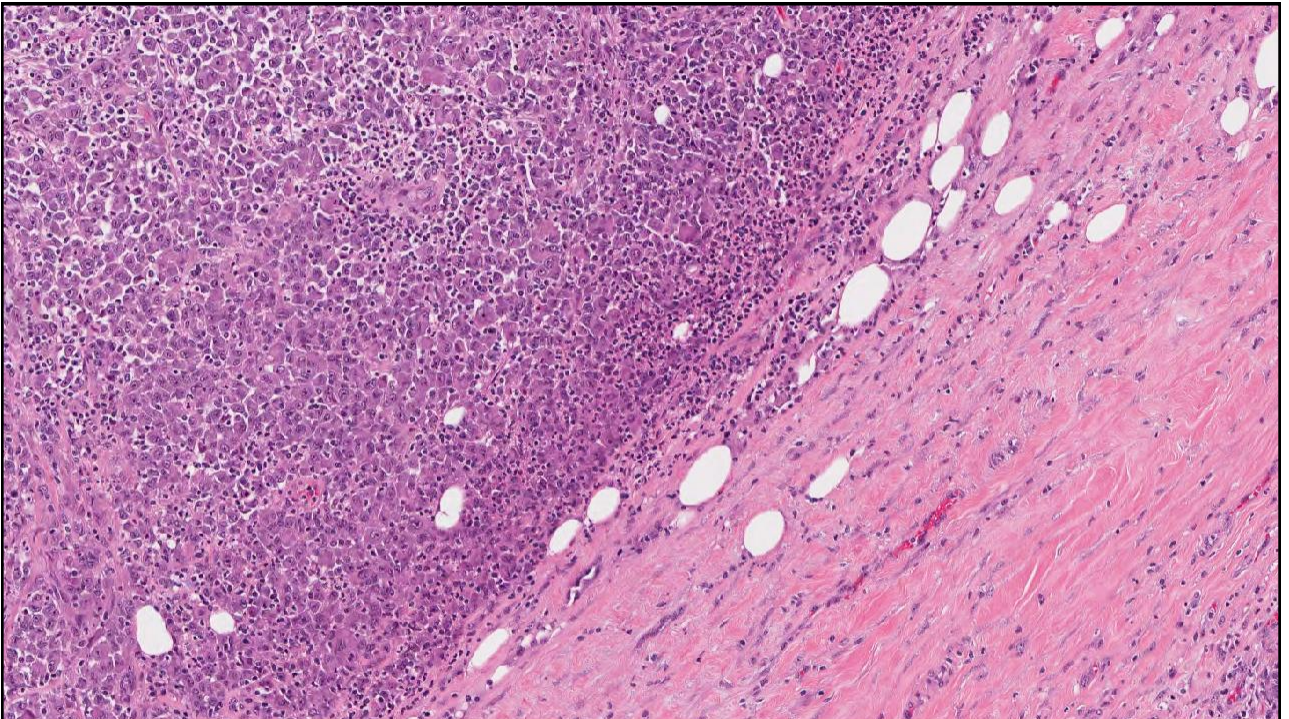
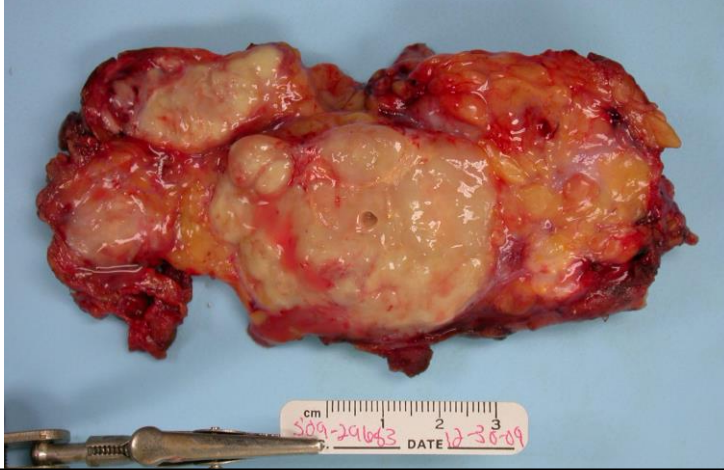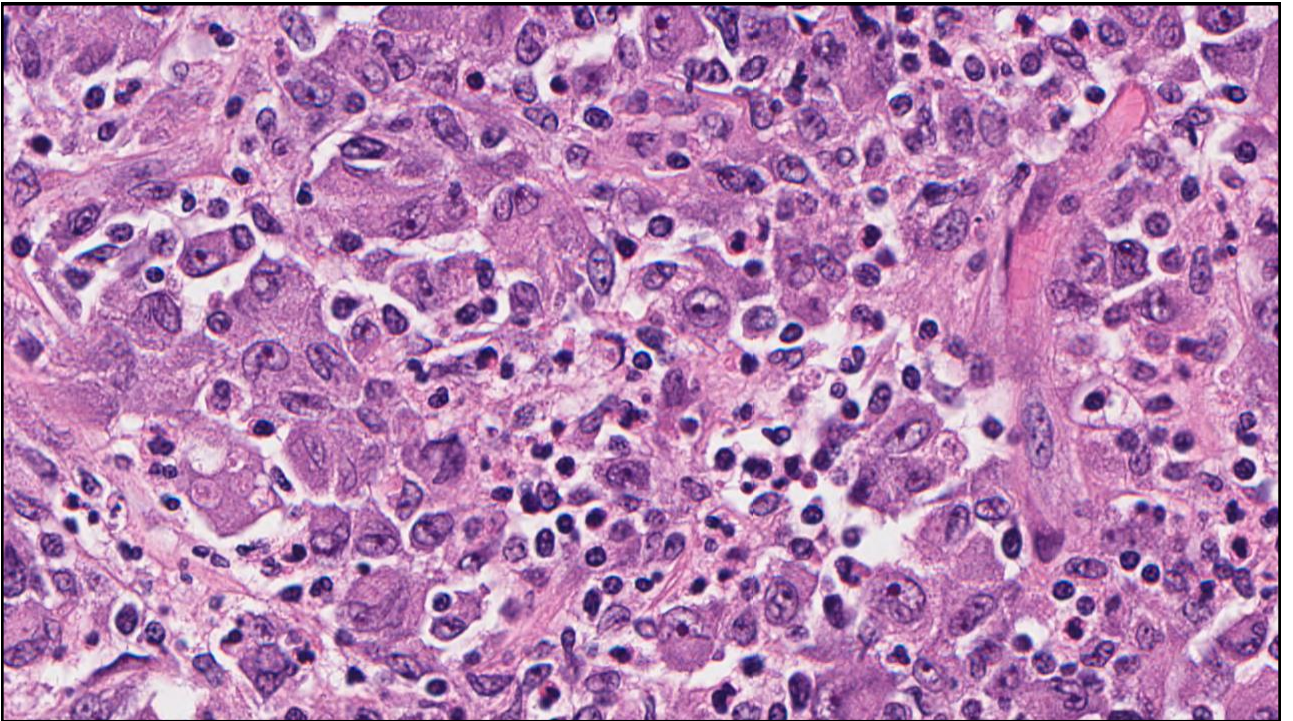
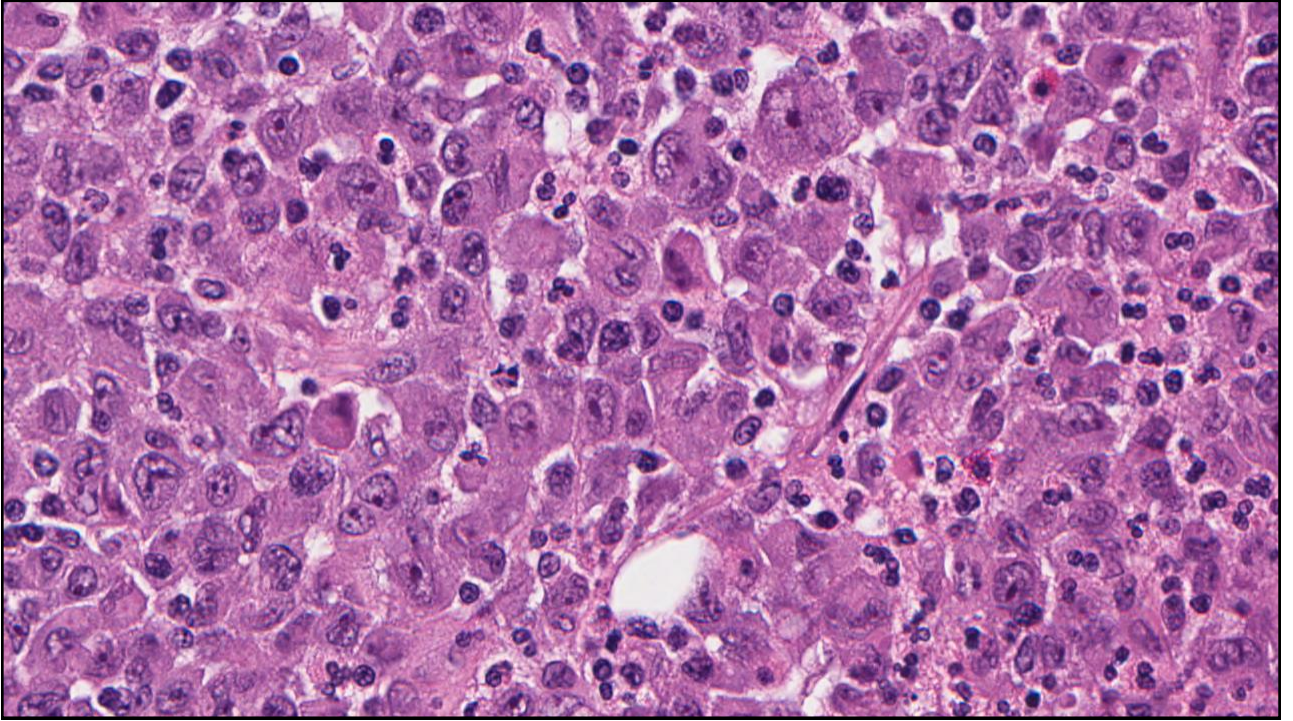
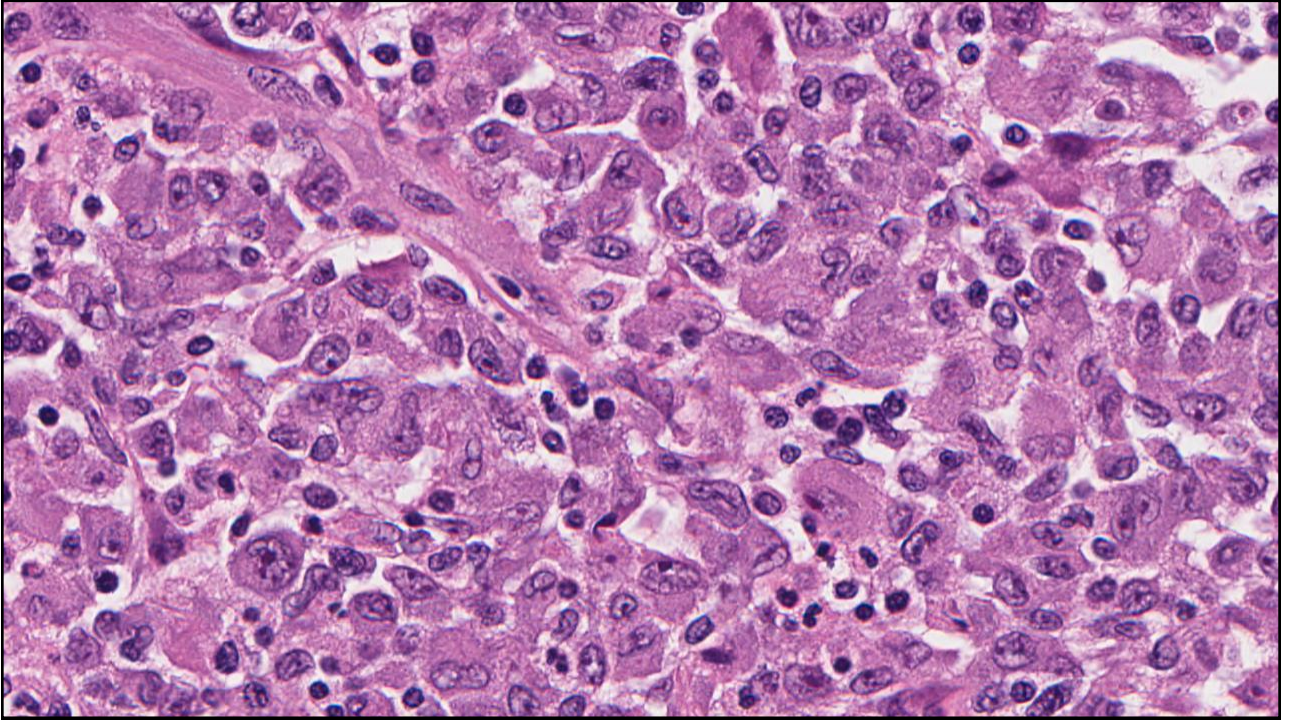


Case 11

- 19 year female bilateral breast masses.







IHC

• Positive

- S100,
- CD1a,
- CD4,
- CD68,
- CD45,
- vimentin and
- CD30 -focally positive

• Negative

- CAM5.2, EMA, cytokeratin AE1/AE3,
- HMB45, Melan A,
- CD3, CD7, CD8, CD5, CD2, ALK-1, CD19, CD20, PAX-5, CD79a, CD138, CD15, myeloperoxidase and lysozyme

Diagnosis

- Langerhans Cell sarcoma

Take Home messages

Unusual clinical features

- Young patient
- Bilateral masses
- Nodal involvement

- Unusual dis-cohesive histology

- Unusual lesions need more thorough work-up